

Annexure 12:


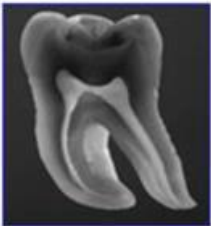

Methods of Identification

Source: *INTERPOL DVI Guide*

Annexure 12: Methods of Identification

12.1. Primary Methods of Identification

It has been internationally accepted that primary identifiers is the most reliable method by which identification can be confirmed. These identifiers are 'Friction Ridge Analysis', 'Forensic Odontology' and 'DNA'. The following symbols are widely used to depict the individual methods of identification.

Primary Identifiers		
Friction Ridge Analysis	Forensic Odontology	DNA Analysis
		

12.1.1. Friction Ridge Analysis

There are three reasons why a friction ridge analysis is a reliable indicator of identity:

1. Friction ridges found on the palmar (palms and fingers) and plantar (soles and toes) surfaces of the human body are unique. Friction ridge formations found on the human body are not repeated on any other person and therefore, this uniqueness enables friction ridges to be used to individualise or exclude persons conclusively.
2. Friction ridges found on the palmar and plantar surfaces of the human body are persistent from birth unless permanently damaged or from advanced decomposition. Papillary ridges are formed in utero and remain unchanged even beyond death. They grow back in the same pattern following minor injuries, whereas more severe injuries can result in permanent scarring. Such changes can still contribute to an identification or exclusion.
3. Friction ridge patterns on fingers (fingerprints) can be classified and searched. Because they can be classified, they can be categorised and registered systematically in a database or collection. Subsequently, impressions can be searched and retrieved easily for comparison and identification.

12.1.2. Forensic Odontology

The unique structures and traits of human teeth and jaws readily lend themselves to use in the identification of living and deceased victims. Dental data can be recovered and recorded at the time of post-mortem examination and compared to ante-mortem data that is supplied by generalist and/or specialist dentists who treated the victim during their lifetime. The teeth are well protected in the oral cavity and are able to withstand many external influences at, near, or after the time of death. Teeth comprise the hardest and most resilient substances in the body, so that when the body's soft tissues deteriorate, the dental characteristics that are so valuable for identification purposes remain accessible. This is especially true of treatments in the teeth, such as restorative and cosmetic fillings and crowns, root canal procedures, implants and fixed and removable prostheses since these are custom-made as unique treatments for each individual. Other anatomical traits can also be compared even when no dental treatments are present, and these also provide useful data for identification purposes.

Conclusions that are available to the DVI odontologists following comparison of post-mortem and ante-mortem dental records include:

- Identification (absolute certainty the PM and AM records are from the same person).
- Identification probable (specific characteristics correspond between PM and AM but either PM or AM data or both are minimal).
- Identification possible (there is nothing that excludes the identity but either PM or AM data or both are minimal).
- Identity excluded (PM and AM records are from different persons).
- Insufficient evidence (neither PM nor AM comparison can be made).

In addition to comparing post-mortem and ante-mortem records to establish identification, odontologists are also able to provide conclusions about certain aspects of a person's life or lifestyle by examining the teeth. These can be valuable when searching ante-mortem databases for potential matches. For example, if the victim is estimated to be a young adult, this might limit the search criteria to certain aspects of the ante-mortem database. Human teeth progress through various stages of development from *in utero* to adult life and these stages of development and tooth 'eruption' can be used to estimate the chronological age of the body at the time of death. Teeth and jaws may contain congenital and/or acquired traits that are useful in determining a person's racial background, dietary and eating habits, and oral hygiene practices. It might be possible, based on the type of dental treatment present, to establish the probable country or region of origin for a given victim. These can then be used to limit or restrict the database to search for possible ante-mortem data for a given body.

12.1.3. DNA Analysis

DNA material is a proven source for identification, as a significant portion of the genetic information contained in a cell is unique to a specific individual and thus differs – except in identical twins, from one person to the next.

DNA testing can be performed even on cases involving partial or severely decomposed remains.

DNA matching is the best way to identify body parts.

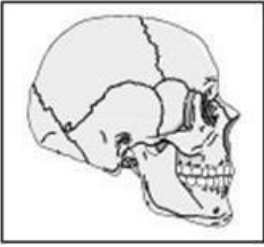

DNA analysis can be automated ensuring maximum quality and rapidity of high volume testing.

DNA matching can be based on profiles from biological relatives, self-samples or belongings and is the only method for primary identification that is independent of direct comparison (e.g. fingerprint records, dental records).

DNA analysis requires a sample to be taken from the deceased body or body parts as well as from known reference material/source for comparison. The samples need to be sent to an accredited laboratory and analysed according to international standards and the profiles compared with the known reference samples (acknowledging that these may not be identical if originating in a biological relative).

12.2. Secondary Methods of Identification

Secondary identifying features have been regarded as secondary in quality whereas this is a temporal definition. Whilst primary identifiers may each individually, or in combination, provide rapid and reliable identification of the deceased, secondary identifiers tend to be used when primary identifiers have failed to secure a verifiable identification. Secondary identifiers in combination may provide sufficient information to make identification in selected cases, and where access to primary identifiers may be limited or absent they may be the only means whereby the deceased can be identified. It is therefore imperative that AM data collection does not neglect the information to be gained from the secondary identifiers.

Secondary Methods of Identification	
Personal Data/Medical Findings	Evidence / Clothing
	

12.2.1. Medical Information

The medical information that is to be collected may be categorized in a number of different ways: External vs. internal, congenital vs. acquired and normal variation vs. disease. This information is mainly acquired by medical professionals, but it may also be advisable to engage the services of a forensic anthropologist in the medical AM collection team.

A personal description consists of basic data (age, gender, height, ethnic affiliation) and specific distinguishing features. Medical findings, such as scars, evidence of disease as well as the surgical removal of organs may provide crucial information about a victim's medical history. Common types of surgery that exhibit few individual characteristics (e.g. appendectomy) should be taken into account in this context. Unique numbers found on heart pacemakers and other prosthetic devices are reliable identifying features. Tattoos, moles and disfiguration may also serve as indicators of identity.

12.2.2. Pathology

Using a plan, the external congenital features to be noted are those that deviate significantly from what is common in the general population for it to be noted by the persons providing AM information, most often close relatives. These are numerous, but some of the more common ones should be mentioned. The shape of the head may be noted as well as peculiarities in the eyes. Eye colour is rarely of much use after death but the shape of the pupil may be of value, as may the size and shape of the nose. In the thorax congenital malformations in the skeleton may be visible externally. In the extremities there are common variations such as pronounced bow knees, absence of or supernumerary fingers and toes and the very common adhesions between fingers and in particular toes.

External acquired features may be the result of disease or may be due to cosmetic surgery or modifications. The former are most often sequelae to trauma in the shape of scars and bony deformities, but skin tumours of a certain size may have been noted by relatives or the general practitioner. Ventral or inguinal hernias are another common feature. The latter are represented by two main groups: Piercings and tattoos. Pierced ear lobes are now so common in women that they are of little use unless multiple, and the ear rings may provide a clue. Pierced ear lobes in the male are relatively common, but are still useful. Piercings may be found in nearly all parts of the body, and since they have often been photographed – the owner perhaps being more extroverted – documentation may be available. Tattoos are also extremely common in both sexes and in all social classes. When they are sufficiently distinctive they may provide support for the identity, but the habit of selecting common or popular art may lessen their value. Cosmetic surgery may need expert attention to be detected but will usually have left scars that may be hidden in natural openings or in folds of the skin. The most common ones are breast implants, and they will be found if a proper autopsy is performed and may in some case carry a serial number, which will then provide a safe identification. This is also true for joint replacement hardware.

Internal features may be very useful, but may need a full autopsy and/or a full body x-ray/CT scan to be documented. It is advisable to perform both since they supplement each other. Congenital or acquired changes in the skeleton are the province of the CT-scan, while peculiarities in the soft tissues such as intestines will most often need the classical autopsy. In both cases the AM information must be precise and as for the radiology comparison between AM and PM radiographs/CT-scans will be useful and necessary. Here the anthropologist may be very useful. There is insufficient space for an exhaustive list of relevant diseases or congenital malformations, the most common ones useful for identification being those that have required operation. This should show up in the medical files during the AM work, such as appendectomy, cholecystectomy, hysterectomy and fractures needing operations such as prostheses, nails and screws. Implants may be very useful, and may actually be critical since pacemakers usually have a unique serial number that may be used to identify the decedent.

12.2.3. Anthropology

In the AM team the forensic anthropologist will be able to address issues pertaining to body variation that will overlap to a greater extent with the information being retrieved by the medical practitioner. The forensic anthropologist will concentrate on hard tissue modifications although they also have extensive experience with soft tissue alterations and particularly those practitioners who have anatomical training. In addition, the forensic anthropologist will be interested in identifying sites of previous fracture regardless of whether orthopedic hardware has been inserted. They will concentrate on diseases and trauma to the skeleton in an attempt to identify verifiable incidents that will link medical records or family recollections with the evidence retrieved at post-mortem. Access to AM radiographs of the missing person will also be of value as it may allow comparison, for example of internal bone architecture or indeed comparison of bone spaces e.g. air sinuses.

12.2.4. Articles / Evidence / Clothing

This category includes all effects found on the bodies of victims (e.g. jewellery, articles of clothing and personal identification documents).

Engraved items of jewellery may provide important clues to the identity of a victim. It is important to consider, however, that certain items of evidence may not actually belong to a given body (e.g. identity papers may be carried by a different person; items of jewellery or clothing may have been lent to another individual; during retrieval, items may have inadvertently been placed in a single, or wrong, body bag). Items of jewellery have a higher identification value if they are firmly attached to a victim's body (e.g. piercings or 'ingrown' wedding rings).

In order to maximise the benefits of these secondary identifiers, investigators should endeavour to access and record details of the relevant items in minute detail. Although many of these property items may be quite common to the public, identifying several items may provide persuasive evidence in cases where they can be used to corroborate other forms of secondary identifiers mentioned above.